



DATE **CLINICAL BACKGROUND & STUDY DETAILS**

3.27.26

PATIENT

Shaela Rohring

SPECIES

Canine

BREED

Miniature Pinscher

SEX

FI

AGE

1.9.16

WEIGHT

22lbs

INTERPRETED BY

Maggie Machen Lamy,
DVM, DACVIM
(Cardiology)

HOSPITAL NAME

Homeward Vound
Veterinary

REFERRING VET

Dr. Vance

INVOICE

47335

History: Presents as a transfer from Atwood due to increased RE and cyanosis during ventrodorsal thoracic radiograph. Occasional coughing at home when overly excited, but not regular. Heart: Normal rate and rhythm, no murmurs or arrhythmias. Lungs: Increased respiratory effort, significant abdominal effort. Abdomen: Possible hepatic or splenic mass noted on abdominal scan.

Current medications: None listed.

Sedation used: Not required to complete full diagnostic ultrasound.

Pertinent previous ultrasound results: No previous.

STAT: Declined at this time.

Imaging performed by: Stephanie Warga RDCS, RVT.

ECHOCARDIOGRAM FINDINGS

2D, m-mode, color flow and doppler imaging is available. The mitral valve is mildly thickened with no prolapse into the left atrial lumen. Trace mitral regurgitation present. There is no left atrial enlargement. There is a normal left ventricular dimension. Left ventricular systolic function is normal. The aortic valve appears trileaflet with normal mobility. The MPA and branches appear slightly dilated. Mild right atrial and right ventricular dilation. Mild/moderate RV hypertrophy. The tricuspid valve is mildly thickened with moderate tricuspid regurgitation. Velocity consistent with moderate pulmonary hypertension. No PI. Normal aortic outflow velocity with no AI. No pericardial/pleural effusion or cardiac masses are seen.

CARDIAC CHART

CANINE CARDIAC PARAMETERS	MR VMAX (m/s)	TR VMAX (m/s)	LA/AO (Boon method)	LA/AO (Heart Base; Swe)	FS (%)	EF (%)	EPSS (cm)
NORMAL PARAMETER	4.5-5.5	<2.7	1.3	<1.6	28-40	40-100	<0.6
PATIENT	NM	4.0	NM	1.3	38	71	NM
CANINE CARDIAC PARAMETERS	HR (BPM)	AV VMAX (m/s)	PV MAX (m/s)	BODY WEIGHT (kg)	LA 2D short axis Base view (cm)	LVIDd Avg; 2D and m-mode short axis (cm)	LVIDs Avg; 2D and m-mode short axis (cm)
NORMAL PARAMETER	50-100	0.7-1.7	0.7-1.6	BELOW	BELOW	BELOW	BELOW
PATIENT	94	1.3	0.9	10.0	1.9	2.7	1.6
*Normal chamber parameters expressed as a mean value (SD)				3	1.27 (5.3)	2.46 (2.46)	1.36 (5.5)
BODY WEIGHT DEPENDENT PARAMETERS				5	1.40 (4.5)	2.74 (5.2)	1.60 (4.7)
*Note: All measurements based upon multi-modal images and methods. An average value is reported.				10	1.50 (3.8)	3.27 (3.5)	2.06 (3.1)
				15	1.83 (2.0)	3.71 (2.4)	2.43 (2.1)
				20	2.02 (1.9)	4.14 (2.2)	2.80 (2.0)
				25	2.18 (2.4)	4.48 (2.9)	3.10 (2.5)
				30	2.33 (3.3)	4.83 (3.9)	3.39 (3.4)
				35	2.48 (4.3)	5.17 (5.0)	3.69 (4.5)
				40	2.62 (5.2)	5.48 (6.1)	3.96 (5.4)
				50	2.88 (7.1)	6.07 (8.3)	4.46 (7.4)

Adapted from June Boon, Veterinary Echocardiography, 1998
Rishniw M and Hollis NE, J Vet Intern Med 2000; 14:429-435
Hansson et al, Vet Rad and Ultrasound 2002
Bonagura et al. Echocardiography: principles of interpretation, Vet Clin North Am 15:1177, 1995

INTERPRETATION OF THE FINDINGS & FURTHER RECOMMENDATIONS

Findings are most consistent moderate pulmonary hypertension. This is based upon right heart/MPA enlargement with moderate tricuspid regurgitation and reported clinical issues. The left side of the heart appears normal with no obvious pathology appreciated. No additional issues are seen.

The underlying genesis of PAH is poorly understood in cases other than heartworm infestation, though it occurs with increased frequency in a variety of forms of chronic lung disease and in patients with idiopathic pulmonary fibrosis. If not performed, a heartworm antigen test is highly recommended.

Given the signalment, chronic pulmonary symptoms and echocardiogram findings, it is likely this patient has underlying lower airway disease (COPD/chronic bronchitis) that over time has begun to affect the heart (PAH). There is likely a primary respiratory issue (infectious, inflammatory, PTE, etc.) that is leading to and being exacerbated by PAH. A PTE should be considered depending on the clinical picture. Patients with significant PAH can eventually develop right-sided congestive heart failure (ascites), debilitating cyanosis and labored breathing and exertional syncope if progressive and poorly controlled.

Medical management of PAH is indicated (Sildenafil), and initial therapeutic dosages are indicated below. Coverage with broad spectrum respiratory antibiotic therapy (fluoroquinolones), oxygen support and Sildenafil is recommended.

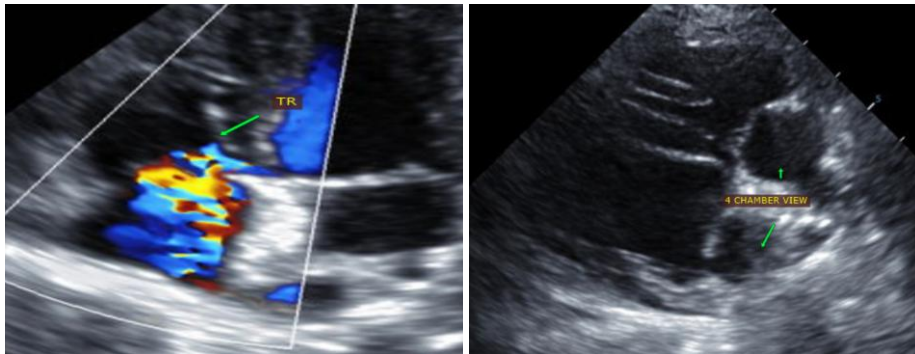
Omega fatty acid supplementation and mild salt restriction may be of some long-term benefit. Monitor for development of a labored breathing, exercise intolerance or collapse episodes.

PLAN

Consider Sildenafil 1-2mg/kg PO q8h; if the patient is doing well at home, decreasing to q12h may be reasonable. Consider heartworm test if not recently performed. Further workup for primary pulmonary disease is recommended as discussed.

A recheck echocardiogram is recommended in 6-12 months to screen for progression, sooner if clinical signs arise.

IMAGES



The information and recommendations provided are based on the images presented by the referring veterinarian. No evaluation can be communicated regarding pathology that was not visible in the image/video clips provided.

Thank you for this referral. This report was generated using transcription software, and minor dictation errors may be present. If the clinical or image interpretation does not parallel your findings or if I can be of any further assistance, please contact me.

Maggie Machen Lamy, DVM
Diplomate of the American College of Veterinary Internal Medicine (Cardiology)
info@sonopath.com